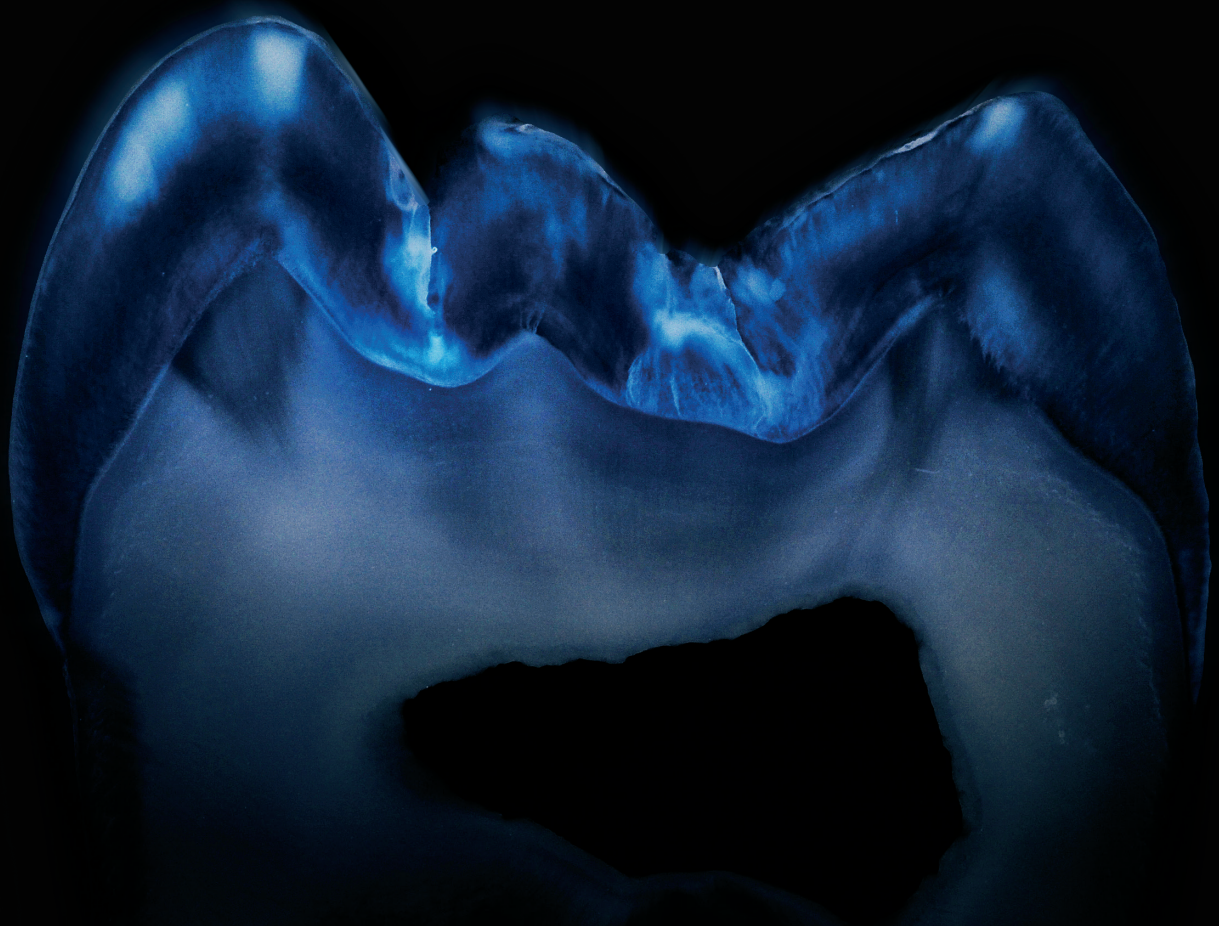


# labline

DENTAVANTGART

VOLUME III ISSUE 04 WINTER 2013



INTERVIEW

THE  
BOUNDLESS  
**MICHEL  
MAGNE**

MDT. BENJAMIN VOTTELER &  
DR. ANDREA KLINK

**PLANNED,  
PRESSED,  
LAYERED**

DR. JORDI MANAUTA &  
DR. ANNA SALAT &  
DR. ANGELO PUTIGNANO &  
DR. WALTER DEVOTO

**ON/OFF**









Dr. Andrea Klink

Benjamin Votteler, MTD

---

GERMANY

# PLANNED, PRESSED, LAYERED

The complex restoration  
of eroded dentition using  
IPS e.max Press

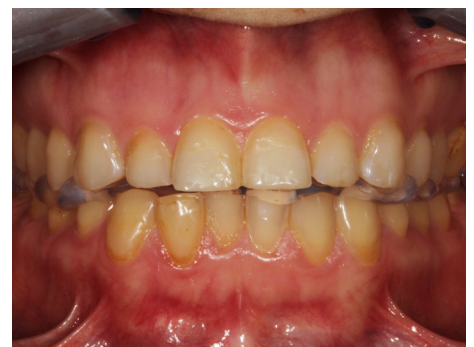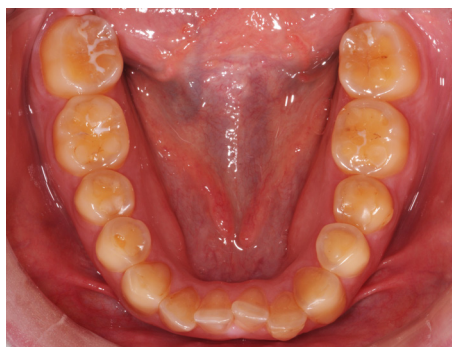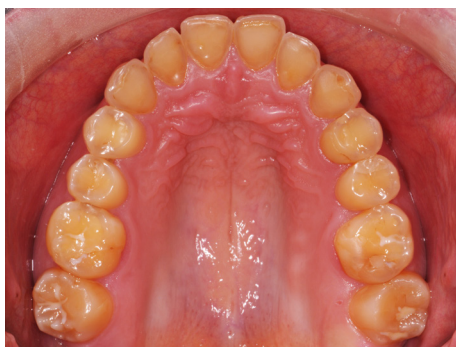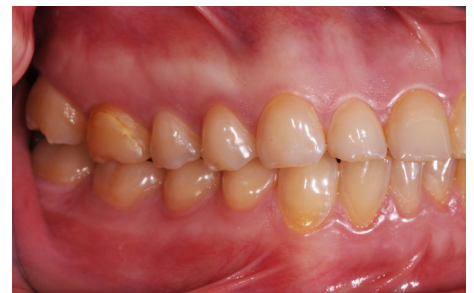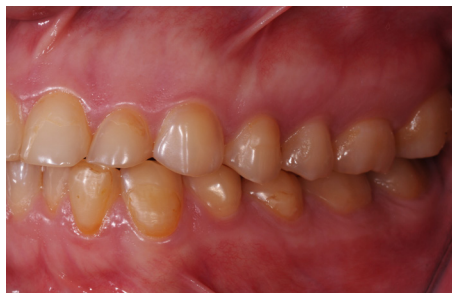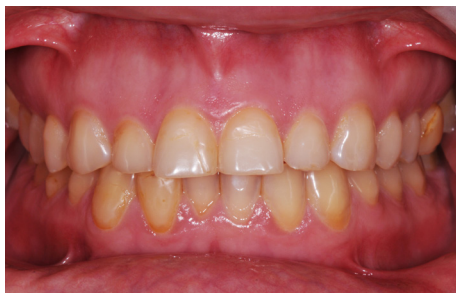## ABOUT THIS CASE

A growing number of people are consulting dental practices about problems that do not involve tooth damage caused by carious processes. The complaints are the result of abrasion and attrition or – as described in the following case – of erosion. The young woman consulted the dental team because she wished to improve the appearance and function of her teeth. The first diagnosis revealed a caries-free adult dentition with lowered bite resulting from two to three millimetres of erosion. The aim of the treatment was to produce a stable long-term prosthetic result, which would correspond to the expectations of the patient. All-ceramic materials provide esthetic, functional and “stable” results in such cases. They restore not only the oral environment, but also the psychological well-being of the patient. The severely eroded dentition demanded a complex treatment plan.

A systematic approach and clinically proven materials (IPS e.max Press lithium disilicate ceramic) were important parameters that contributed to the success of the treatment. After the treatment, the young woman did not have any functional problems and she was able to chew properly. She was particularly impressed with the esthetic results. All the “wheels” in this treatment process functioned smoothly. The patient regained her well-being and self-esteem. Some of the many treatment steps are shown here and help to visually illustrate this case.

## PRE-OPERATIVE SITUATION

**First consultation:** The patient reported that she was not able to chew and bite properly. She also complained that her incisors, in particular, were too short due the loss of enamel as well as too dark and yellow.



**1.1** The initial examination revealed a caries-free dentition with composite build-ups on the labial surfaces of the upper anterior teeth as well as in many occlusal areas of the posterior teeth.

**1.2** Lateral view of the pre-operative situation. The speaking distance and the position of rest showed a loss of vertical dimension of two to three millimetres.

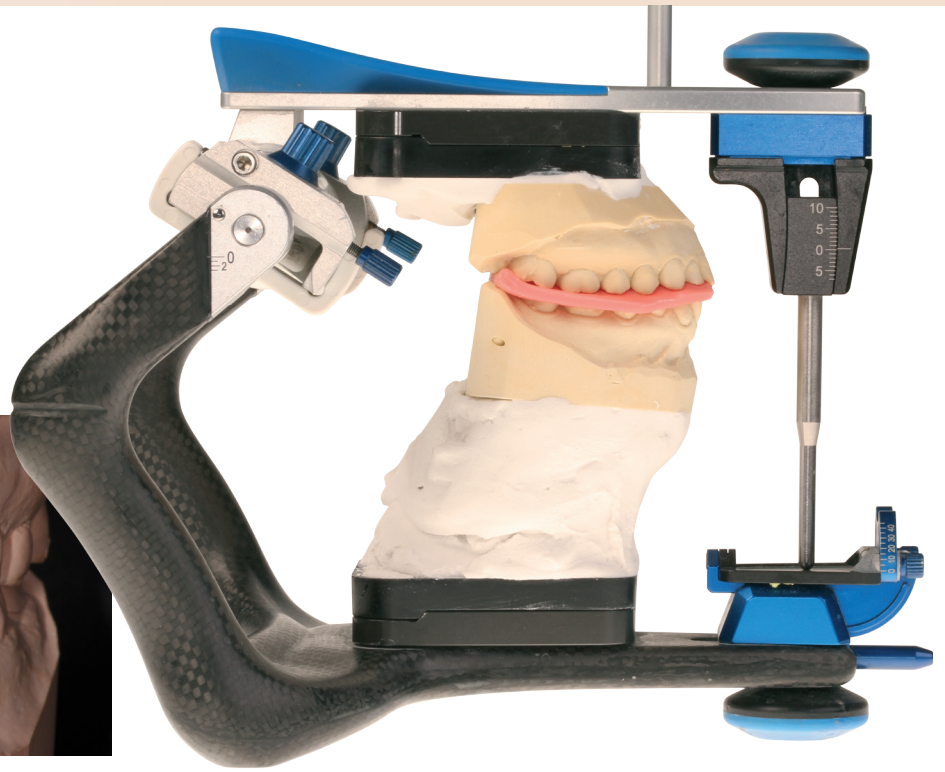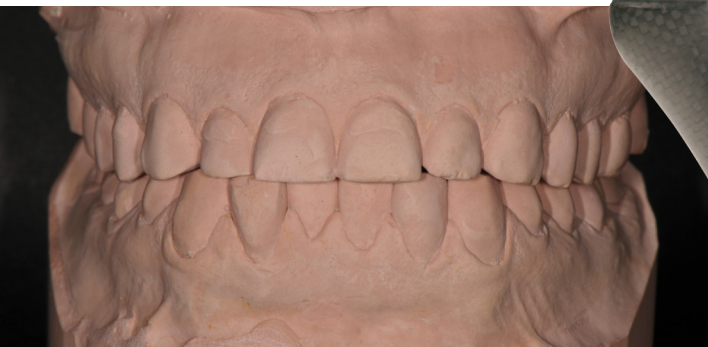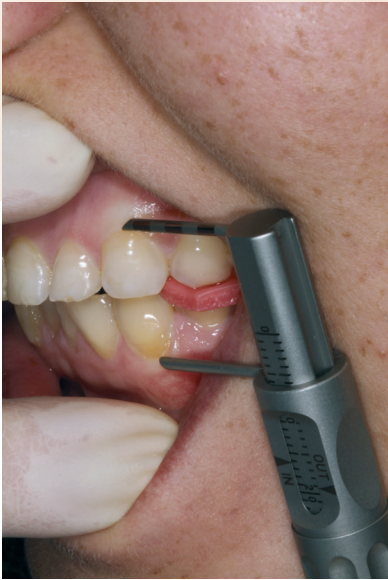**1.3** No functional abnormalities were determined. The chewing, neck and shoulder muscles showed only moderate tenderness on palpation. The temporomandibular joints did not show any tenderness on palpation.

**1.4** Occlusal view of the upper jaw. Erosion-related defects of this type are usually caused by chemical processes.

**1.5** Occlusal view of the lower jaw. Foods and beverages with a low pH can cause tooth structure to erode. In this case, the patient was found to have consumed cola beverages for many years.

**1.6** The diagnosis included the exact evaluation of the anatomic casts and a functional analysis. The examination showed Class 1 occlusion with static contacts on all the teeth.





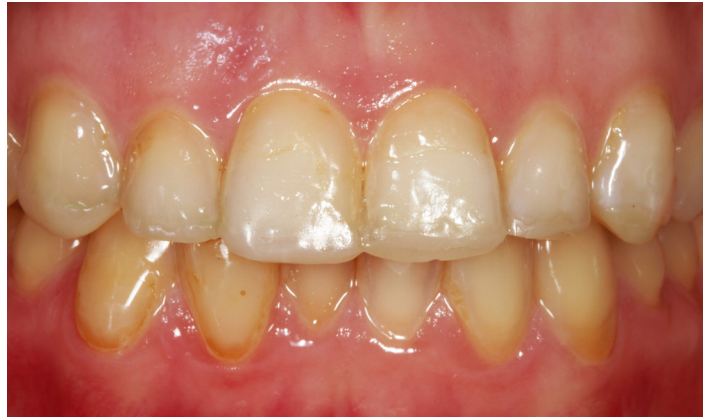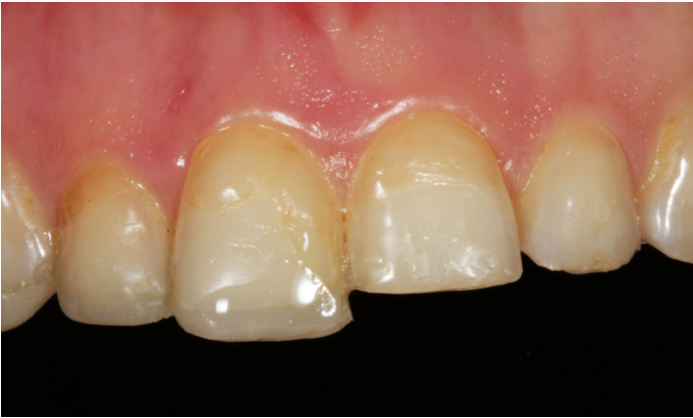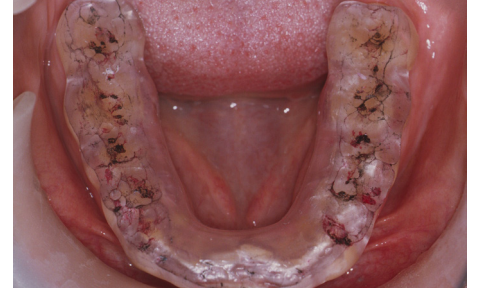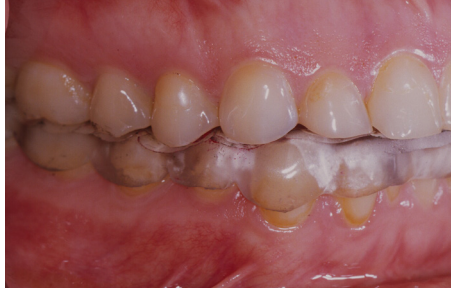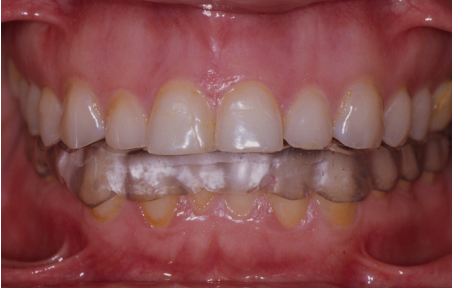**1.7** The new vertical dimension of occlusion was verified. The fabrication of an occlusal appliance was planned, which would help to restore the vertical dimension. A vertical increase of 2.5 mm was determined.

**1.9** The basis for the fabrication of the occlusal appliance with equilibrated occlusion: The models were placed in the articulator in accordance with the new vertical dimension (HeadLine determination according to Schöttel/Plaster) (Rotofix, Amann Girrbach AG), (beauty pink wax plate, Moyco).

**1.8** Pre-operative situation  
In addition to the anatomic impressions of the two jaws, a bite record of the new vertical dimension was made for the laboratory (anaxdent matrix flow, anaxdent).



## PRE-TREATMENT



■ ■ ■ **2.1** An appliance was used to achieve a unilateral balanced occlusion. The load-bearing cusps of the upper posterior teeth had to show punctual contacts in a single line on the appliance during static occlusion.

■ ■ ■ **2.2** During dynamic occlusion, the canine and the premolar had to show laterotrusive contacts. Additional laterotrusive, mediotrusive and retrusive contact surfaces had to be removed.

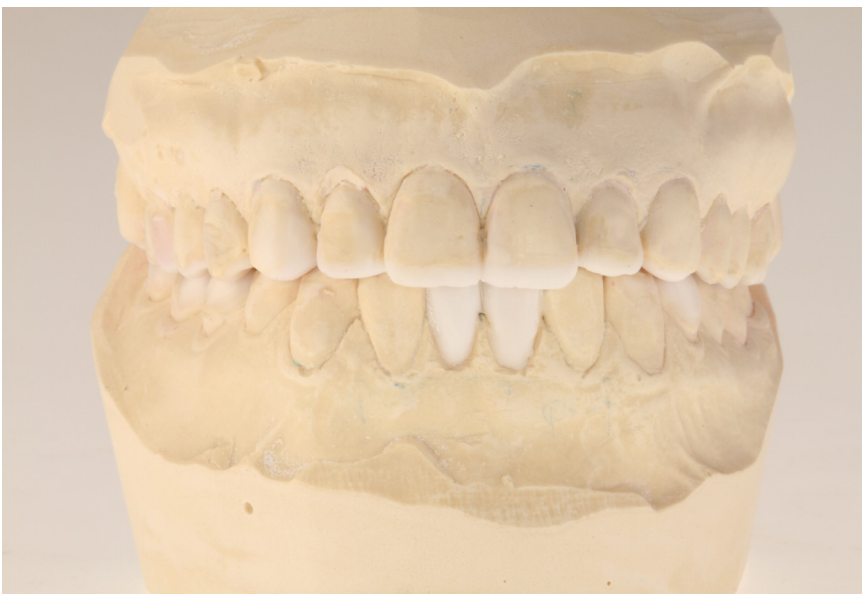
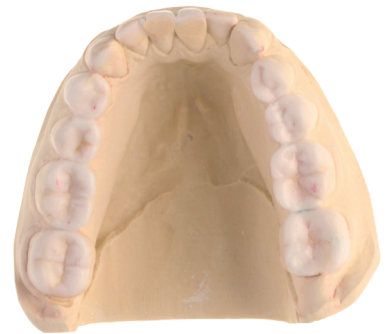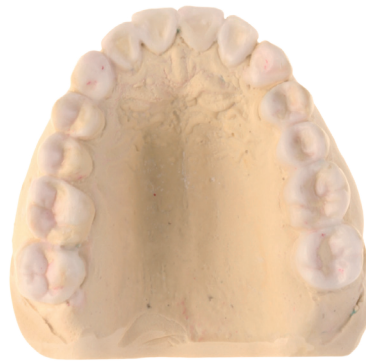■ ■ ■ **2.3** The patient was instructed to wear the appliance for 24 hours a day for a period of six months. During this time, the appliance was adjusted on several occasions.

■ ■ ■ **2.4** In order to test the expected result, a mock-up was created in the anterior region.

■ ■ ■ **2.5** The mock-up was used to evaluate the esthetic and phonetic parameters in the practice.



**2.6** The mock-up also gave the patient an initial impression of the anticipated outcome.



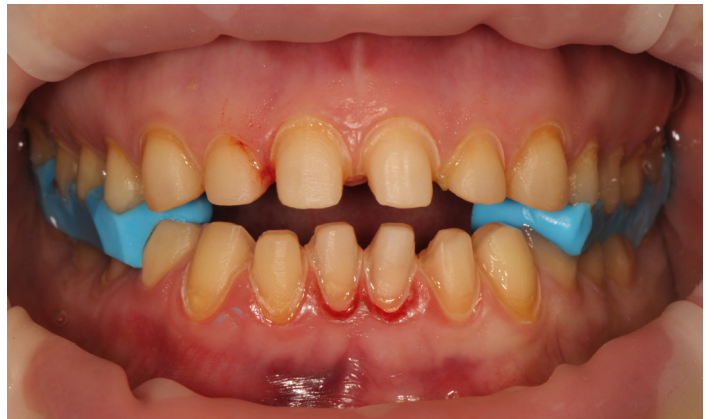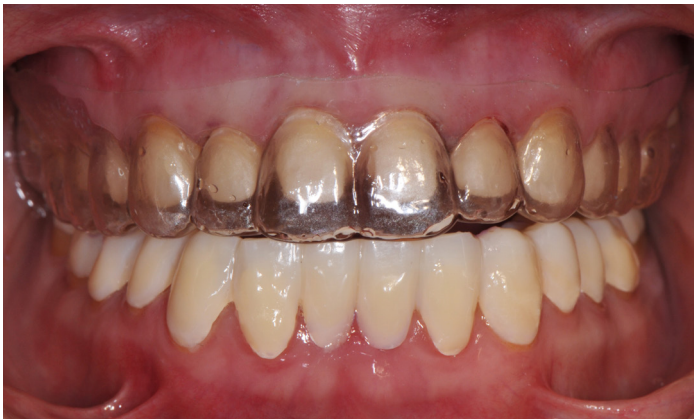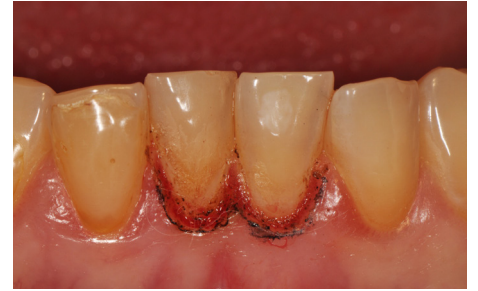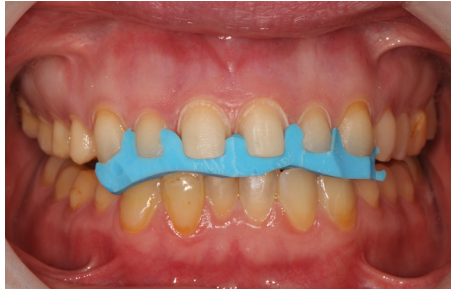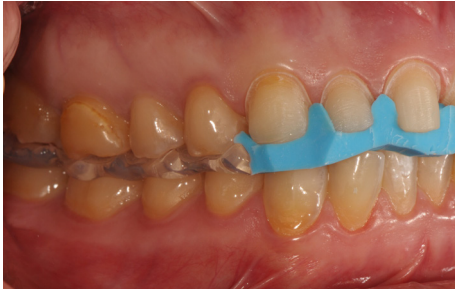**2.7** An impression was taken of the lower jaw with the appliance in place. Then the model was placed in the articulator in accordance with the upper jaw and the adjustable anterior guidance table was programmed.

**2.8** A wax-up was modelled according to the functional and esthetic parameters, and the preparation and space requirements were documented.

**2.9** Ideal physiological situation. The existing structures were built up in the wax-up by additive means.



## PRIMARY PREPARATION (PRACTICE)



■ ■ ■ **3.1** Preparation of the maxillary teeth: The vertical dimension defined by the appliance must be exactly maintained.

■ ■ ■ **3.2** Preparation of the maxillary teeth: A sequential preparation method allows the operator to take a very structured approach in the adjustment of the supporting areas by separating the bite record into thirds (imprint bite, 3M Espe).

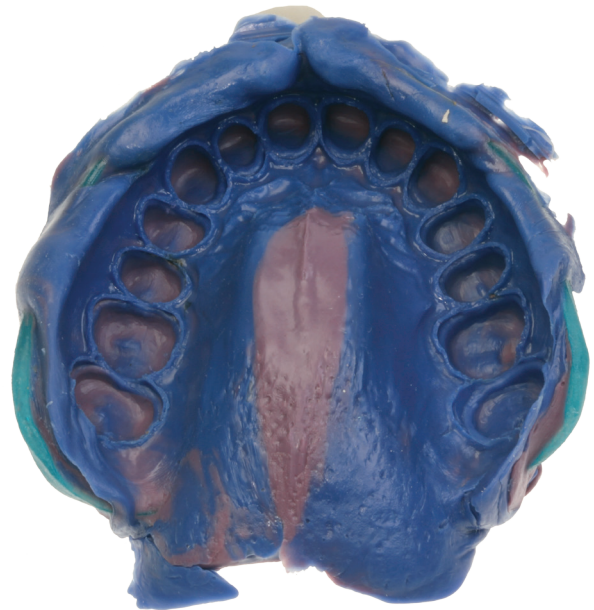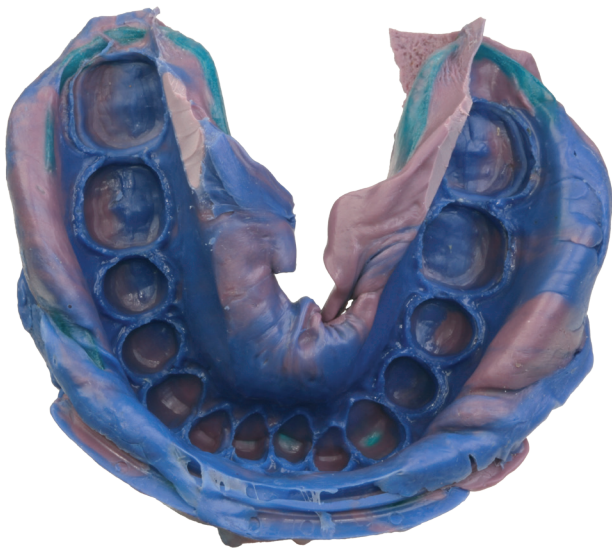
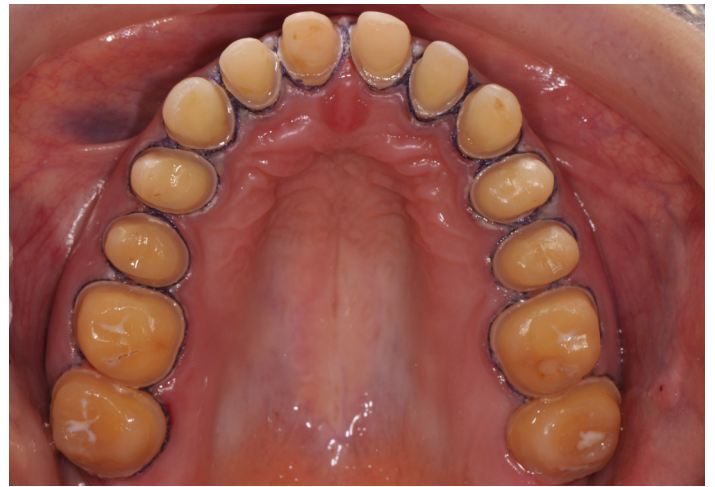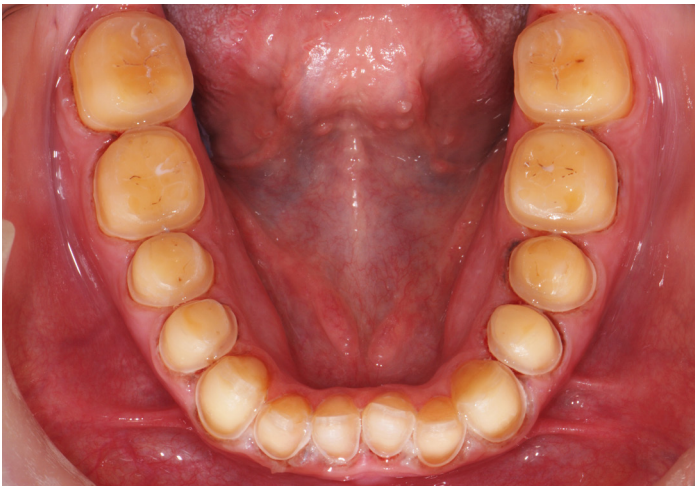■ ■ ■ **3.3** The crowns of tooth 31 and 41 (labial) were surgically/clinically lengthened to optimize the appearance of the gingival margin.

■ ■ ■ **3.4** During the preparation procedure, a transparent vacuum-formed tray, which was fabricated with the help of the duplicated waxed up models, was used to check the space requirements of the restorations.

**3.5** The chairside provisionals were fabricated on the basis of the vacuum-formed tray, which took into account the new vertical dimension. The tray was produced with the help of the duplicated models of the wax-up.

■ ■ ■ **3.6** Due to the sequential method used in the preparation of the maxillary teeth including bite registration, the mandibular teeth could be prepared at a second appointment, without any loss of vertical dimension.





**3.7** The prepared mandibular teeth. The maxillomandibular relationship was provisionally recorded during preparation.

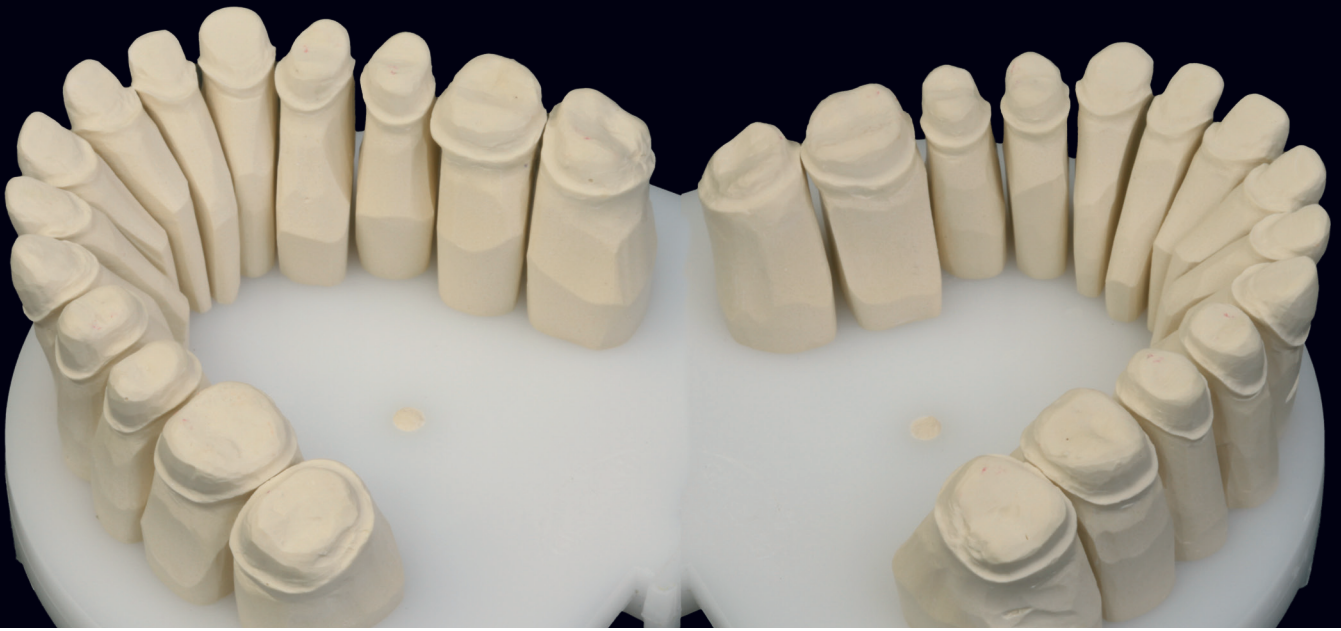
**3.8** The maxillary teeth ready for impression-taking.

**3.9** Impression of the lower jaw (double-cord technique, polyether impression material) (Impregum/Permadyne, 3M Espe)

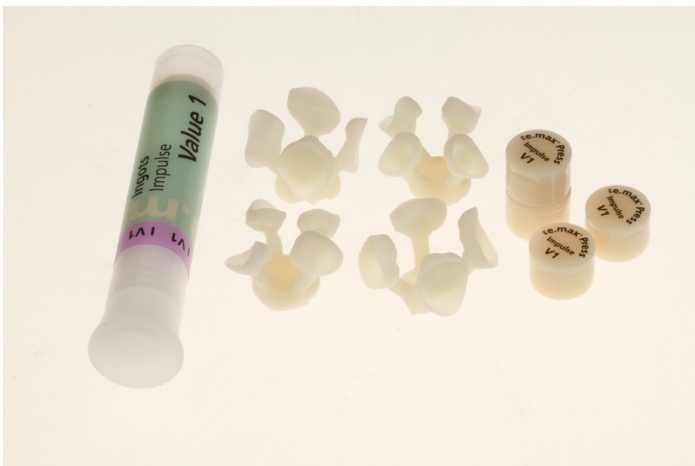

**3.10** Impression of the upper jaw (double-cord technique, polyether impression material) (Impregum/Permadyne, 3M Espe).



## FIRST LABORATORY PHASE AND TRY-IN



4.1 The working models for the fabrication of the permanent posterior restorations (press ceramic single crowns) and the anterior crowns (long-term temporaries) (giroform, Amann Girrbach AG)



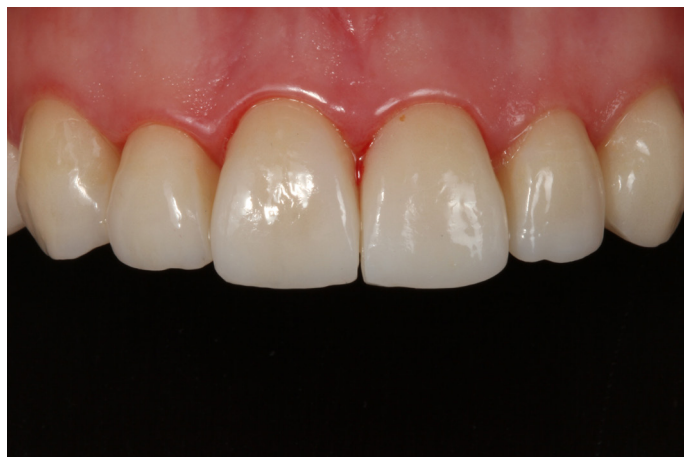
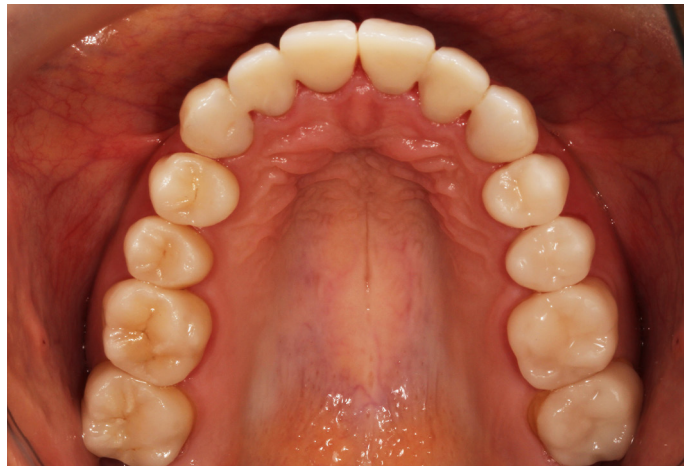
**4.2** The long-term temporaries for the anterior dentition were milled from a composite resin blank (Telio CAD) using CAD/CAM methods. Subsequently, they were characterized.

**4.3** The models were transferred to the articulator again with the help of a facebow or by HeadLine determination (Schöttel/Plaster) (Rotofix, Amann Girschbach AG, beauty pink wax plate, Moyco).

**4.4** After the digitalization of the models, the tooth shapes which had been selected from the tooth library were adjusted to the wax-up. Subsequently, they were milled in wax and then reproduced with press ceramic.

**4.5** Precision fit of the pressed crowns after cleaning with acid and blasting medium.

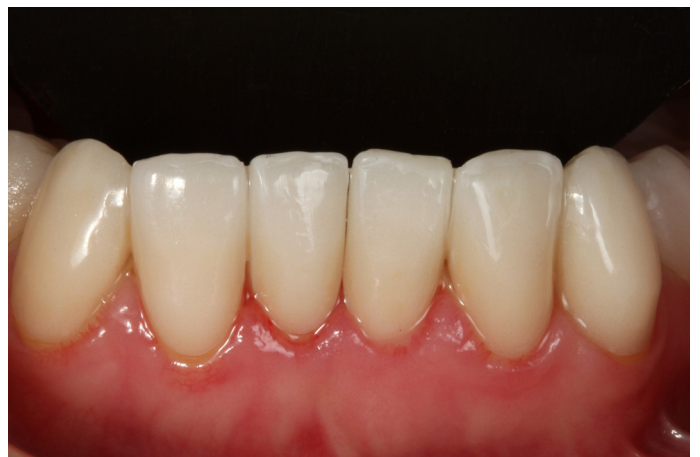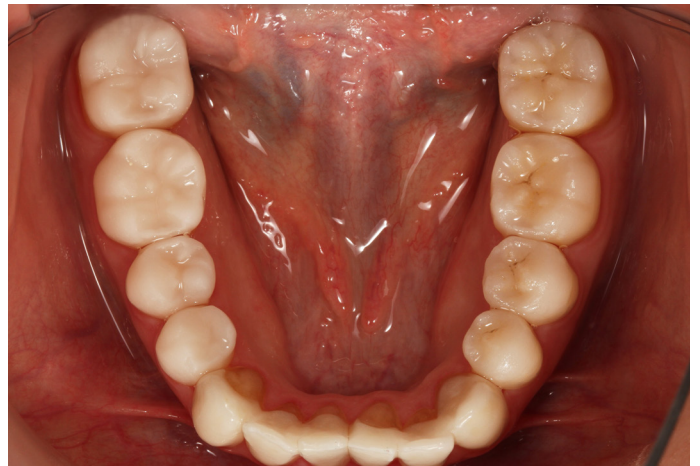


**4.6** Try-in of the restorations in the mouth of the patient: The monolithic posterior crowns in the 1st and 3rd quadrant have been characterized to evaluate their colour, but they have not yet been glazed (!).

**4.7** For the try-in, the posterior crowns of the diagonally opposed parts of the jaw (1st and 3rd quadrant) were characterized.

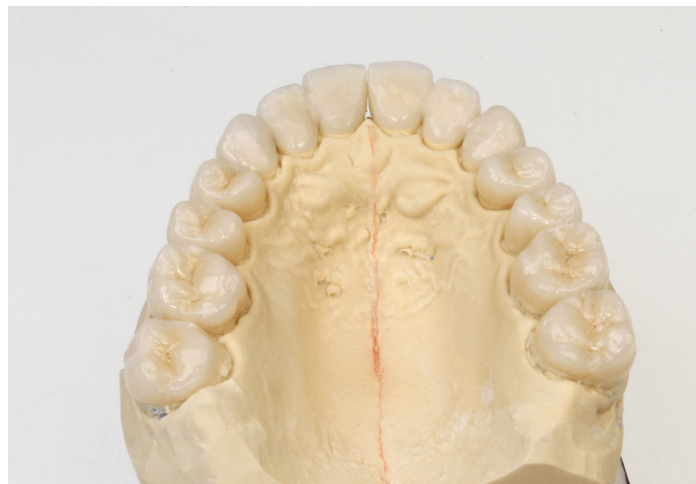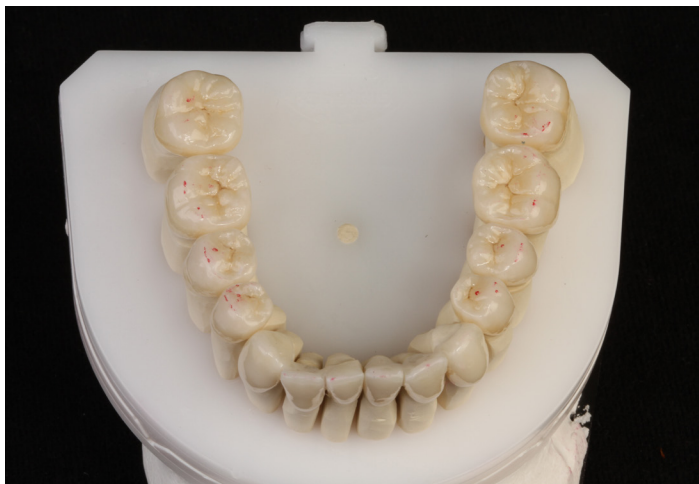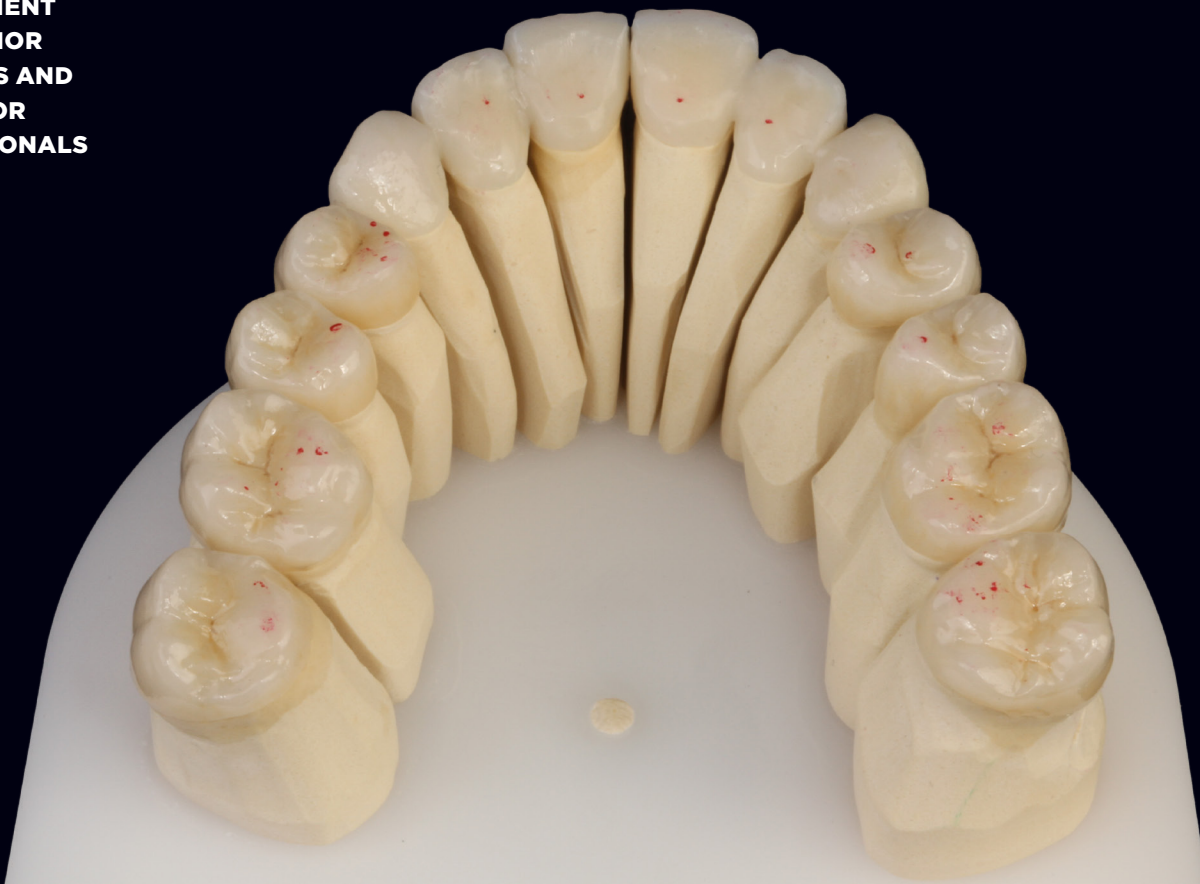
**4.8** Try-in of the upper anterior long-term temporaries. The dentin cores of the crowns were machined using CAD/CAM methods and the incisal areas were individually layered.

**4.9** Try-in of the lower anterior long-term temporaries





**PERMANENT  
POSTERIOR  
CROWNS AND  
ANTERIOR  
PROVISIONALS**



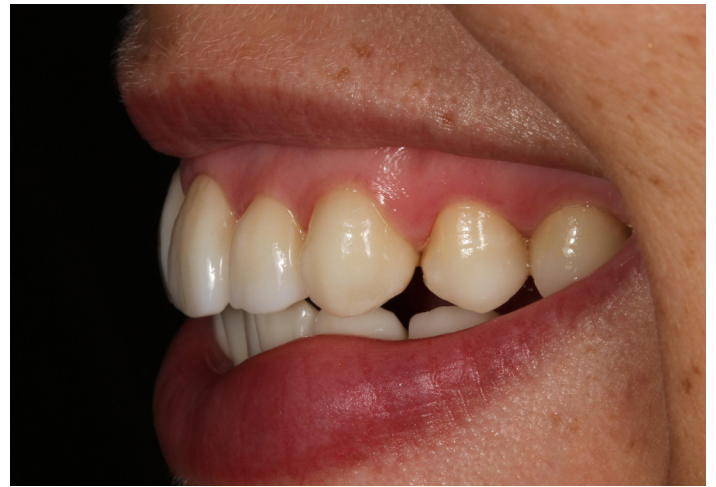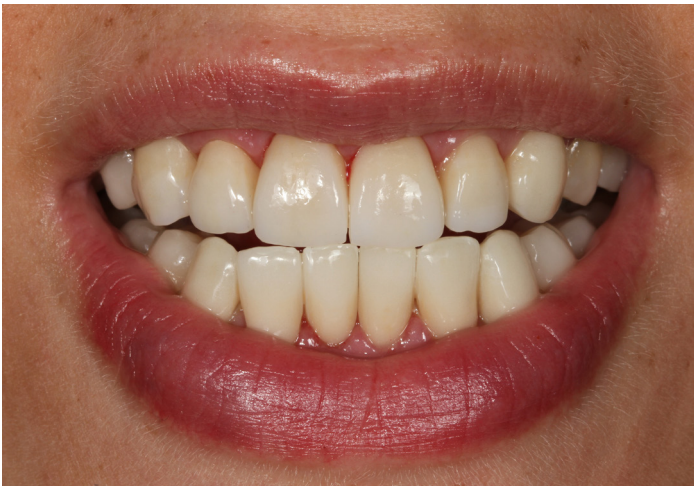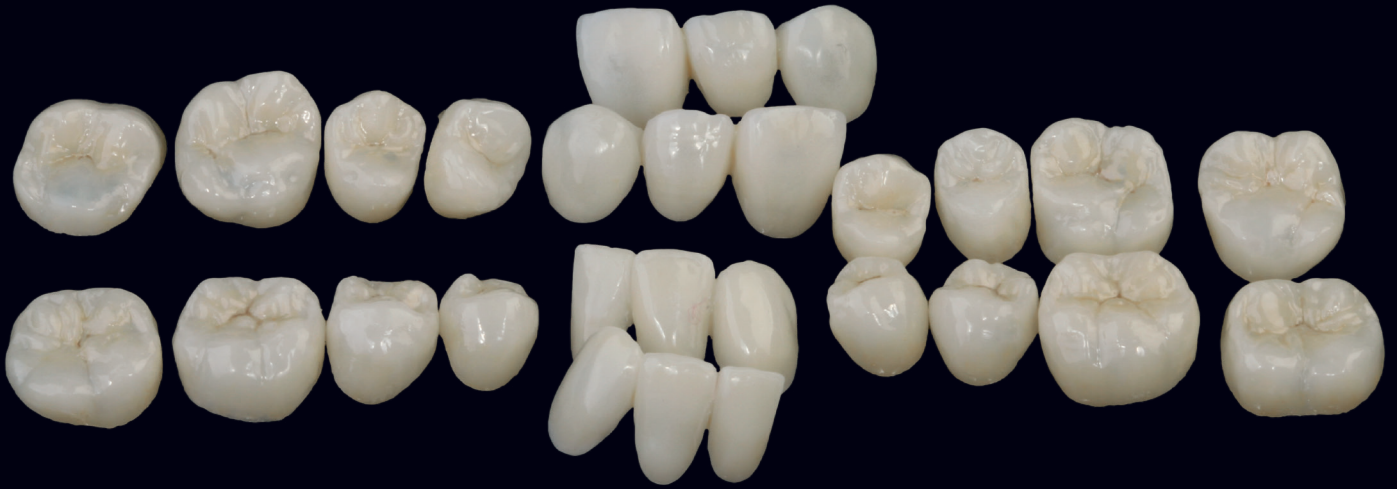**5.1** The permanent restoration on the maxillary model. The posterior crowns (final) have been characterized and glazed. Long-term temporaries (PMMA) have been fabricated for the anterior teeth.



**5.2** The permanent restoration on the mandibular model after the try-in. Full-contour ceramic crowns have been produced for the posterior teeth. Long-term temporaries (PMMA) have been fabricated for the anterior teeth.



**5.3** Palatal view of the model with the restorations. The vertical dimension of occlusion corresponds to the situation established with the occlusal appliance.

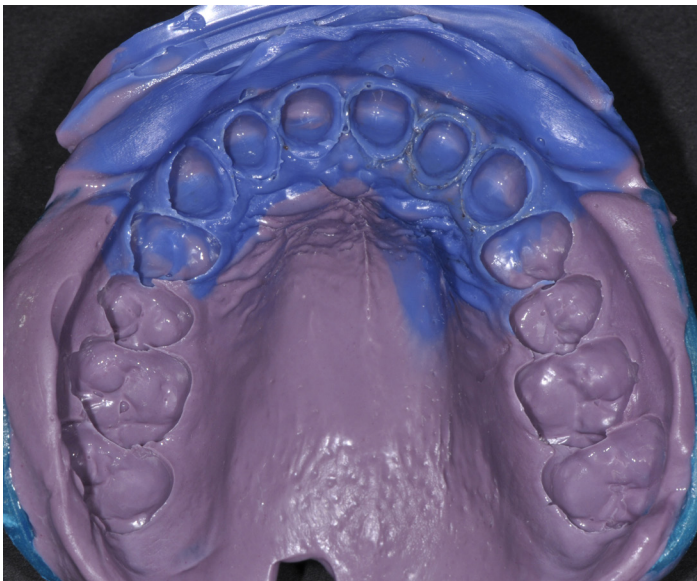
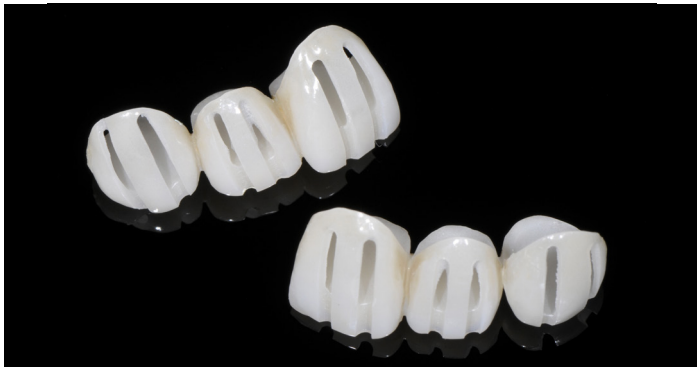
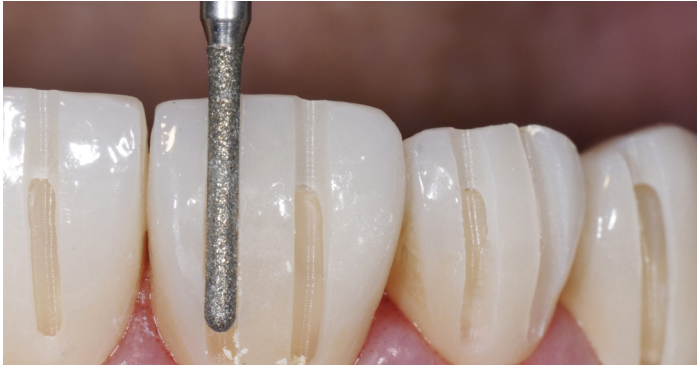
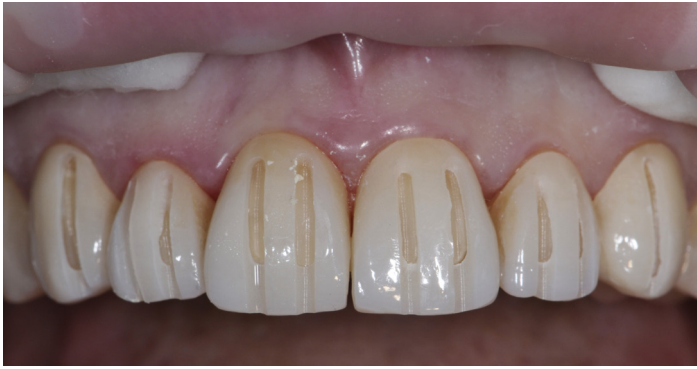**5.4** The completed crowns are ready for placement. Posterior teeth: all-ceramic crowns; anterior teeth: long-term temporaries

**5.5** After the posterior crowns and the anterior provisionals were placed, the patient was given the opportunity to test the restorations for a period of two to three months.

**5.6** The patient was able to evaluate the esthetic and functional parameters of the restorations and show off her new appearance to family, friends and colleagues.





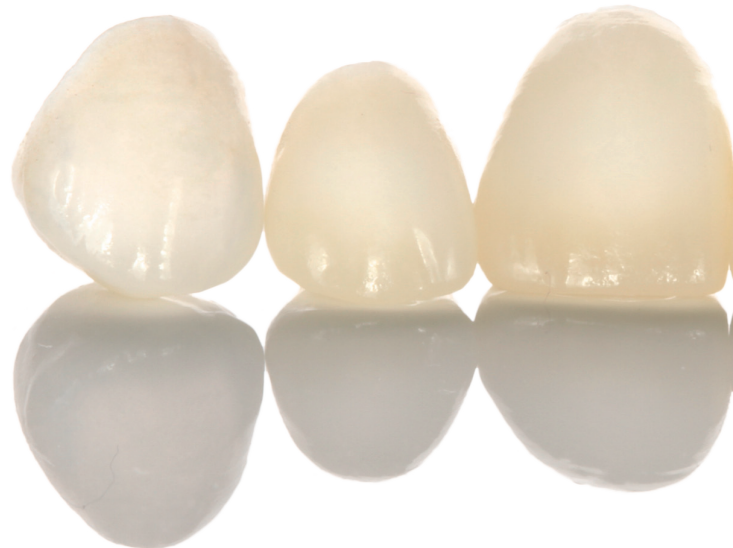## SECONDARY PREPARATION (PRACTICE) AND SECOND LABORATORY PHASE

**6.1** Three months later, the anterior teeth were prepared according to minimally invasive principles.

**6.2** In order to adhere to the principle of preserving tooth structure, the re-preparation of the anterior teeth took place through the long-term temporaries, with the help of a red-ringed diamond bur (diameter of 1.2 mm).

**6.3** The long-term maxillary temporaries after their removal from the prepared anterior teeth.

**6.4** Impressions of the upper and the lower jaw were taken again using the double-cord technique (Impregum/Permadyne material). The patient was released from the practice with new provisionals.



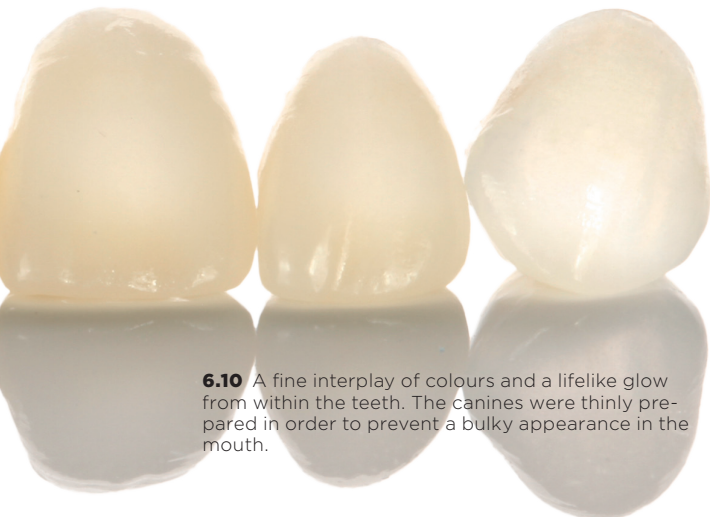**6.5** The master casts for the fabrication of the permanent anterior crowns for the upper jaw and the veneers for the lower jaw.

**6.6** Lithium disilicate was chosen for the framework. The excellent properties of the material would enhance the esthetic appearance of the restoration.

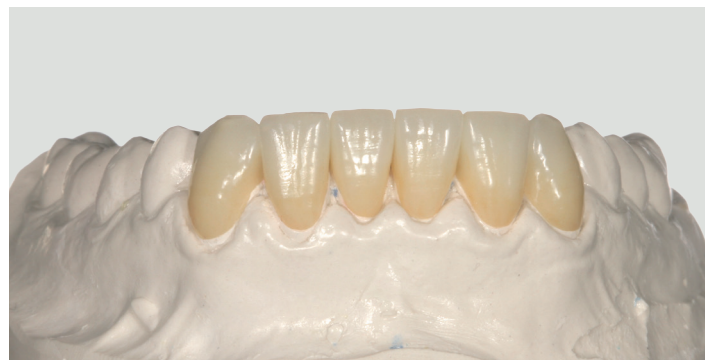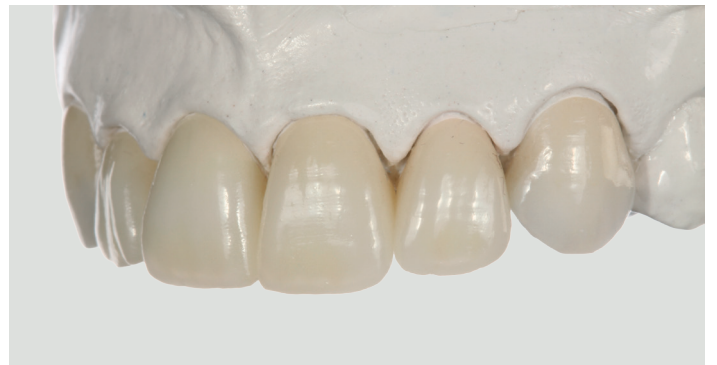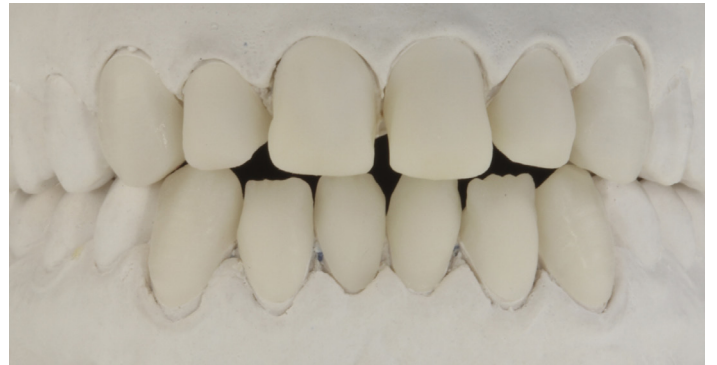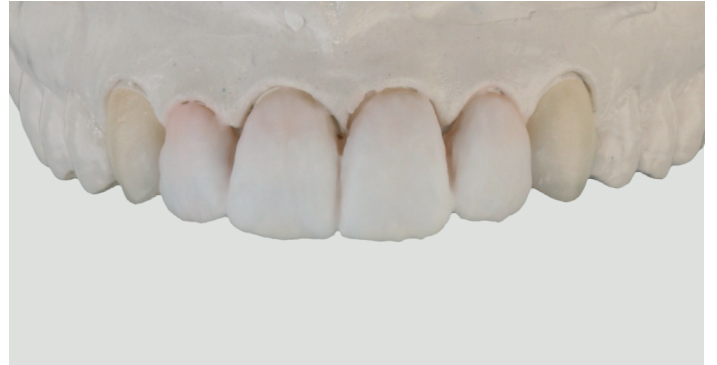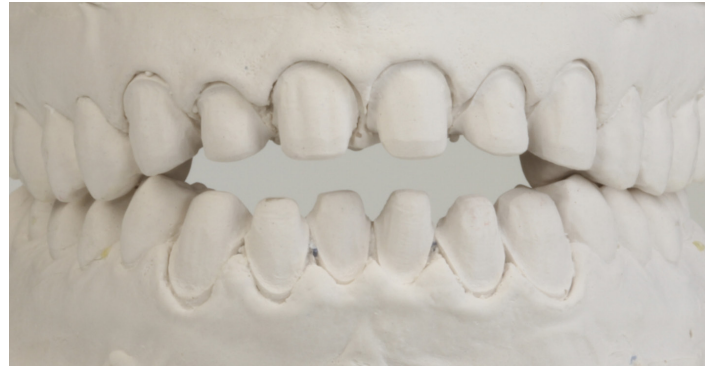**6.7** The restorations were individually layered (IPS e.max Ceram) in coordination with the selected press ingots (IPS e.max Press LT A1).

**6.8** The anterior crowns (upper jaw) look very natural on the model. Following the creation of a true-to-nature surface texture, the crowns were manually polished in preparation for their placement.

**6.9** Due to the specific materials used, a fine interplay of colours was achieved, and as a result, a lifelike glow from within the teeth.



**6.10** A fine interplay of colours and a lifelike glow from within the teeth. The canines were thinly prepared in order to prevent a bulky appearance in the mouth.

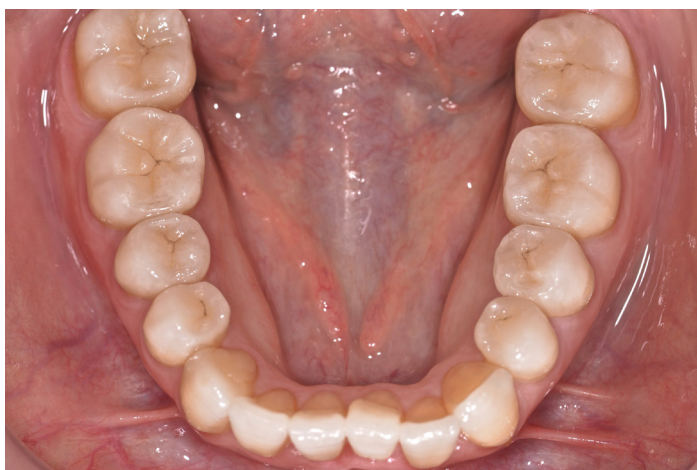
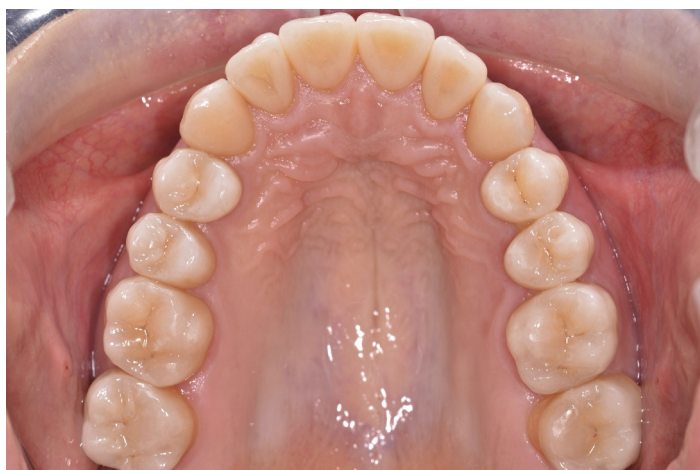
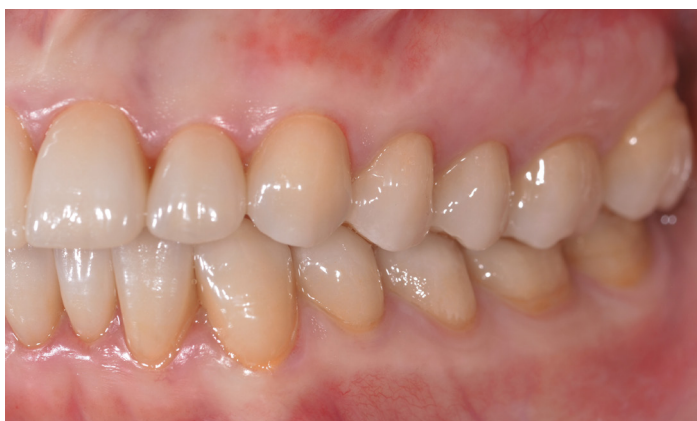
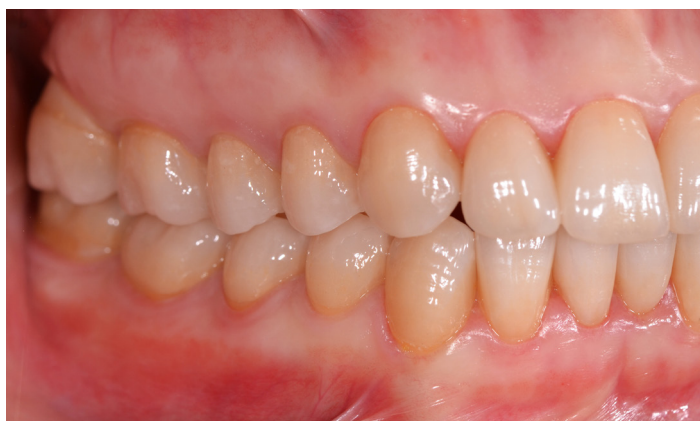
**PLACEMENT  
AND RESULT**





**7.8** Two months after the placement of the restorations, the condition was stable in terms of both occlusion and function. According to the patient, she has fully regained her well-being and self-esteem.











 **7.1** Lateral view of the crowns placed with the adhesive technique.


 **7.2** Lateral view of the crowns placed with the adhesive technique.

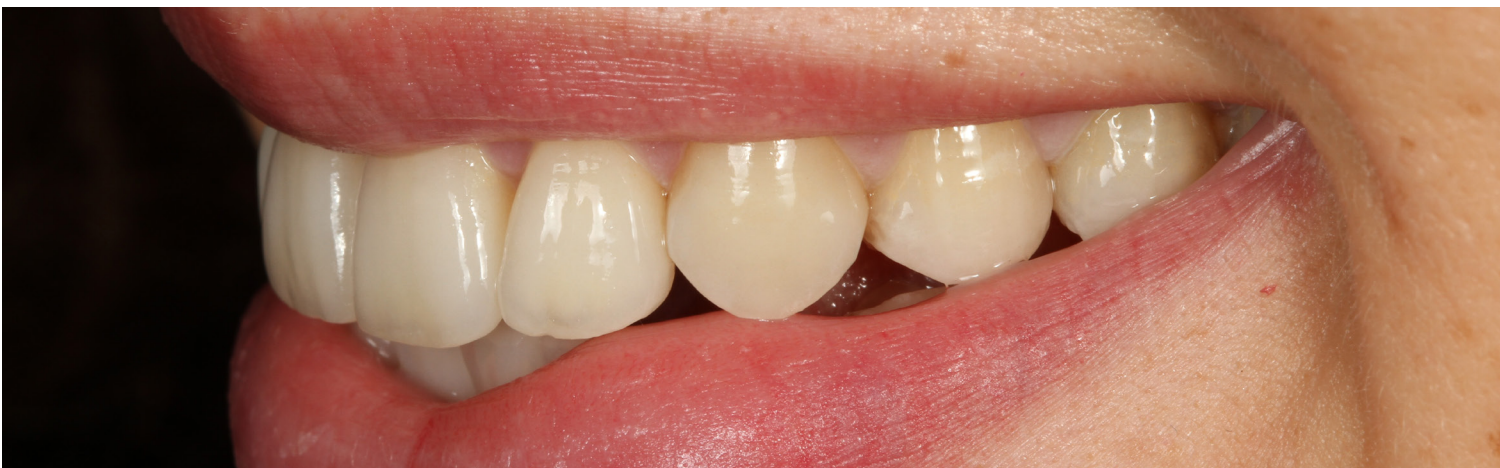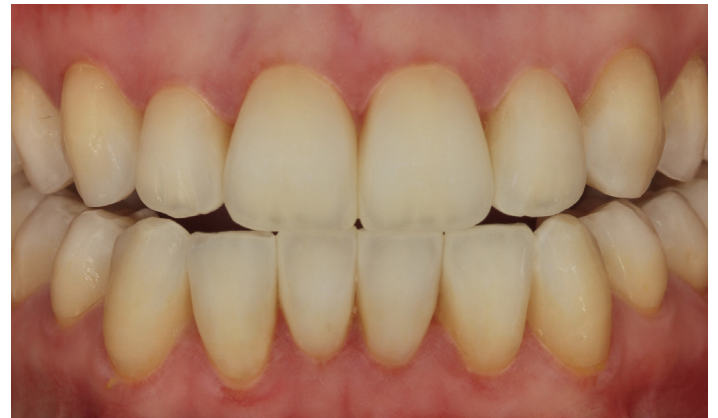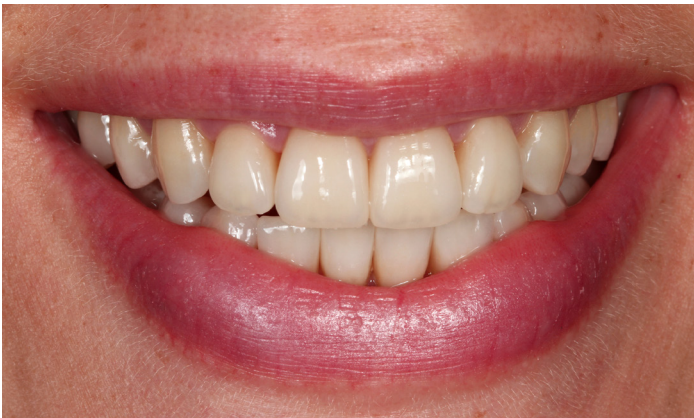 **7.5** Dynamic occlusion: The functional parameters were checked after the crowns had been placed, and they were found to be ideal.

 **7.6** Determination of the brightness value: This picture was taken with a linear polarizing filter. As a result, the observer is not distracted by any reflections.

 **7.3** Occlusal view of the restored upper jaw. The single crowns look almost like natural teeth and therefore blend in smoothly with the oral environment.

 **7.4** Occlusal view of the restored lower jaw. Despite the fact that the posterior crowns were fabricated with the staining technique, the result looks highly esthetic.

 **7.7** Lateral view of the smiling patient; esthetic integration of the anterior teeth within the mouth and the face of the patient.











The self-confidence with which the patient "flirted" with the camera after the complex treatment was the perfect compliment for the entire dental team.

## THE PRODUCTS

The following products from Ivoclar Vivadent were used in the case presented. For more information about these products, simply tap on the individual fields.

**IPS e.max® Press LT**  
Press ingots

**IPS e.max® Press Impulse**  
Press ceramics

**Variolink® II**  
Esthetic dual-curing luting composite

**Telio® CS C&B**  
Self-curing temporary crown and bridge material

**Syntac®**  
Total-etch adhesive

**IPS e.max® Ceram**  
Layering ceramics

**IPS e.max®**  
CeramShades, Essence, Glaze Staining materials

**Telio® CAD**  
Long-term temporaries

**Multilink® Automix**  
The adhesive luting system

**SR Nexco®**  
Laboratory composite

**BENJAMIN VOTTELER**  
DENTAL TECHNICIAN, GERMANY

Benjamin Votteler, MDT, achieved the best results in his year in the final examinations of his dental laboratory technician training in 2001. From 2001 to 2005 he travelled extensively and gained practical experience at prestigious dental labs in the Stuttgart area, in Switzerland and in the US. He qualified as a Master Dental Technician in Stuttgart in March 2006. Since then he has been running a dental laboratory together with his father in Pfullingen, Germany. Benjamin Votteler is well-known internationally as an author of numerous publications and as a lecturer. He specializes in all-ceramic restorations. He conducts hands-on workshops to share his skills and knowledge

**Benjamin Votteler, MDT**  
Dentaltechnik Votteler GmbH & Co KG

Arbach ob der Strasse 10  
72793 Pfullingen  
Germany

dentaltechnik@votteler.eu  
www.votteler.eu

**WDR ANDREA KLINK**  
DENTIST, GERMANY

Dr Andrea Klink decided to become a dentist after having completed her training as a dental lab technician. She studied dentistry at the University of Tübingen from 1999 to 2004. Dr Klink has worked as a research associate in the Section of Medical Materials and Technology of the Department of Prosthodontics (Medical Director: Prof. Dr Heiner Weber) at the University of Tübingen since 2004. She is passionate about her work on fixed dentures and all-ceramic restorations in particular. Dr Andrea Klink has a deep interest in highly complex, esthetic and functional treatment cases, which she believes can only be resolved with well-structured and rigorous treatment plans. In addition to her practical work, she is also Principal Investigator of the research group "Medical devices & technology" at the University of Tübingen.

**Dr. Andrea Klink**  
Poliklinik für Zahnärztliche Prothetik

Osianderstrasse 2-8  
72076 Tübingen  
Germany

andrea.klink@med.uni-tuebingen.de





*We wish all our Readers  
a Merry Christmas  
and a Happy New Year!*

PHOTO: DR. MENTES ÁRPÁD



**labline**

[www.labinemagazine.com](http://www.labinemagazine.com)



**facebook**

[www.facebook.com/  
Labline Magazine](https://www.facebook.com/LablineMagazine)



**DentAvantgArt**

9400 Sopron, Virágvölgyi u. 59.  
[www.dentavantgart.hu](http://www.dentavantgart.hu)  
[info@dentavantgart.hu](mailto:info@dentavantgart.hu)